



Review Article

Ulcerative Colitis in Elderly People: An Emerging Issue

Wei-Chen Lin^{a, b, c}, Ming-Jen Chen^{a, b, c}, Cheng-Hsin Chu^{a, b, c}, Tsang-En Wang^{a, b, c},
Hornng-Yuan Wang^{a, b, c}, Chen-Wang Chang^{a, b, c*}

^a Division of Gastroenterology, Department of Internal Medicine, MacKay Memorial Hospital, Taipei, Taiwan, ^b MacKay Junior College of Medicine, Nursing and Management, Taipei, Taiwan, ^c MacKay Medical College, Taipei, Taiwan

ARTICLE INFO

Accepted 25 April 2018

Keywords:

elderly,
endoscopy,
inflammatory bowel disease,
ulcerative colitis

SUMMARY

Ulcerative colitis (UC) is a common cause of chronic gastrointestinal disease in the developed world, which has a bimodal age distribution, with 10–30% of the affected population older than 60 years. Elderly patients with UC will be seen more frequently with the aging of the population and increasing incidence of UC. The management of UC in the elderly population is more complex due to comorbidities and polypharmacy. This review article provides a brief up-to-date comprehensive summary of the epidemiology, diagnosis, and management of UC, with a focus on the special caring for elderly patients. Clinical challenges in the diagnosis of elderly patients with UC and the adverse effects or benefits of treatment options have been described.

Copyright © 2019, Taiwan Society of Geriatric Emergency & Critical Care Medicine.

1. Introduction

Ulcerative colitis (UC) and Crohn's disease (CD), collectively known as inflammatory bowel disease (IBD), are common causes of chronic gastrointestinal disease in the developed world. UC has a bimodal age distribution with an initial peak in the third decade and a smaller second peak between the ages of 50 and 80 years.^{1,2} UC in elderly patients may be either long-standing or late-onset UC, where a diagnosis is made at a later age. These two distinct groups of older UC patients have different clinical course. Late-onset UC may be associated with less disease progression and the risk of colorectal cancer in long-standing UC is well established.¹ Approximately 10–30% of patients with UC are older than 60 years and 10–15% are first diagnosed in older age.³ In the aging population, the incidence of UC is expected to increase. Therefore, physicians should be aware of comorbidities, drug interactions, and predisposing factors for infection in elderly patients, in order to optimize therapeutic management and intervention.

2. Epidemiology

In the Western countries, late-onset UC is more common than CD and has increased incidence in elderly men.¹ UC is more common in Asia, and its incidence and prevalence have rapidly increased over the past two to four decades.⁴ In Taiwan, the incidence of UC increased from 0.61 per 100,000 person-years in 1998 to 0.98 per 100,000 person-years in 2008.⁵ At the time of diagnosis, 28.6% of

patients with UC are >60 years. Of these, 58% present in their 60s, and 34% in their 70s.⁵ Former smoking status is a prominent risk factor in elderly people.²

3. Clinical features

Common symptoms of UC include diarrhea, bloody mucous stool, rectal bleeding, and/or rectal urgency.⁶ Elderly patients with UC tend to have less rectal bleeding and more atypical presentations of paradoxical constipation and fever, which may result in delayed diagnosis (Table 1).^{7–9} With regard to disease location, according to the Montreal classification, left-sided UC are more common in elderly patients than in younger patients.^{1,10} Elderly patients have better initial responses to therapy 1 year after diagnosis.^{2,7} Disease extension rarely occurs during follow-up in elderly people.¹¹ However, elderly patients have higher rates of sepsis and surgery and greater mortality even when they have similar severity over the whole disease course as young adult patients.⁷ This may result from inadequate control of UC activity, and aggressive treatment with immunomodulators and biologic agents confers a risk of infection in elderly patients.^{3,10}

4. Diagnosis and differential diagnoses

The diagnosis of UC should be based on medical history, clinical evaluation, and typical endoscopic and histological findings.⁶ A typical endoscopic finding is continuous and confluent inflammation involving the rectum with or without proximal continuous extension into the colon.⁶ The histological diagnosis is based on two main components: architectural change (glandular distortion and epithelial cell abnormalities) and inflammatory status (basal plasmacytosis and neutrophil infiltration).⁶ There are some prevalent disorders

* Corresponding author. Division of Gastroenterology, Department of Internal Medicine, MacKay Memorial Hospital, No.92, Sec. 2, Chung-Shan North Road, Taipei, Taiwan.

E-mail addresses: mky378@yahoo.com.tw (C.-W. Chang).

Table 1
Clinical features of elder and young adult UC patients.

Clinical manifestation	Elder patients	Young patients
Symptom	atypical presentations of constipation and fever	more rectal bleeding and diarrhea
Initial severity	mild	severe
Initial response to therapy	better response	poor response
Disease location	more left-sided colitis	more extensive colitis
Disease extension	rarely	common
Sepsis, surgery and mortality	higher in the whole disease course	higher in the 1st year

that mimic UC and should be considered initially in elderly patients, which otherwise delay the appropriate treatment. The differential diagnoses include infections, ischemia, drug-related complications, and radiation colitis (Table 2).

4.1. Infective colitis

Infective colitis is common in elderly people, which is difficult to differentiate from UC with concomitant bacterial infections, due to the endoscopic and histological findings that overlap with those of UC.¹² *Aeromonas* species and *Clostridium difficile* are common pathogens in chronic infective colitis and UC.¹³ However, bloody diarrhea, decreased response to antibiotic treatment, and histological features of cryptitis and crypt abscess are important features in the diagnosis of UC with bacterial infection.¹³

Cytomegalovirus (CMV) infection is common in elderly UC people with comorbidities (most commonly chronic renal insufficiency and diabetes mellitus) or who have been hospitalized for other conditions. The clinical presentations are diarrhea, hematochezia, tenesmus, abdominal pain, and bloody diarrhea.¹⁴ The endoscopic appearance is usually nonspecific and limited to the left colon, which is indistinguishable from UC.¹⁵ Three identified features were well-demarcated ulcerations, ulceroinfiltrative changes, and pseudomembrane formation.¹⁶ Histological specimens of viral intranuclear inclusions (as owl's eye appearance) confirm the diagnosis.¹⁷

4.2. Ischemic colitis

Ischemic colitis (IC) occurs with greater frequency in elderly people, especially in patients with comorbidities of diabetes, dyslipidemia, heart failure, or peripheral arterial disease.¹⁸ Compared with UC, features of IC are abrupt-onset abdominal pain, short-disease course, and mild anemia.¹⁹ Endoscopic findings which distinguish IC from UC are the segmental distribution, rectum sparing, and rapid resolution on serial examinations.²⁰ The definitive histology of IC include the detection of mucosal infarction, clots or fibrin in the capillaries, or submucosal hemorrhage.²¹

Table 2
Differential Diagnosis of ulcerative colitis in the elderly.

	Distinguishing features	Distinguishing findings
Infective colitis	response to antibiotics	positive stool culture
Cytomegalovirus colitis	comorbidities of renal failure or diabetes mellitus	endoscopy and histology
Ischemic colitis	short term disease course	endoscopy and histology
Drug-related colitis	medical drug history	endoscopy and histology
Radiation colitis	history of radiation therapy	histology

4.3. Drug-related colitis

Medications including nonsteroidal anti-inflammatory drugs (NSAIDs), estrogens, digitalis, and sodium phosphate (NaP) can induce colitis.⁹ The most common drug is NSAID because it is widely used for arthritis and other painful conditions in elderly people. The common symptoms of drug-related colitis include abdominal pain, diarrhea, and blood in stools. The typical endoscopic appearance is sharply demarcated ulceration with adjacent normal mucosa.²² The histology of NSAID-related colitis shows no evidence of chronic features (crypt distortion, basal plasmacytosis, Paneth metaplasia), and increasing mucosal eosinophils is a common feature in most drug-related colitis.²³ Oral NaP is widely used for bowel preparation for its good tolerability and effective bowel cleansing ability. However, NaP would cause colitis, especially in the distal colon and rectum.²⁴ The histologic findings range from edema, hemorrhage, and mononuclear infiltration to increased epithelial crypt proliferation and apoptosis.²⁵

4.4. Radiation colitis

Radiation colitis is also common in the elderly population with a history of radiation over the lower pelvis, and the symptoms are diarrhea, urgency, bleeding, pain, or tenesmus.²⁶ Endoscopy can reveal friability and granularity, erythema, or prominent telangiectasias, which mimic UC. Classical histologic findings are epithelial meganucleosis and fibroblastic proliferation.²⁶

5. Treatments

The treatment of UC in elderly patients is the same as that in younger patients; however, therapeutic approaches for UC in this unique population have been based on expert opinion and data extrapolated from clinical trials that may or may not have included elderly patients.^{3,10} The elderly population, independent of functional status, is often excluded due to comorbidities and polypharmacy and concern about drug interactions.^{3,10,27} The treatment of UC depends on the severity and location of disease.⁶ The goals of treatment are to induce and maintain remission, prevent complications, and improve the quality of life.^{3,6}

5.1. Aminosalicylate

The first-line therapy for elderly patients with mild to moderate UC is oral 5-aminosalicylate (5-ASA) (2.0–4.8 g/day).¹ Topical 5-ASA is an effective therapy for proctitis and left-sided colitis. The combination of oral and topical 5-ASA is more effective in extensive UC.⁶ However, topical therapy in elderly patients presents special challenges relating to sphincter incompetence and poor coordination skills to self-administer.²⁸ 5-ASA has a side effect of nephrotoxicity due to slower elimination of drugs and should be carefully administered to elderly patients with poor renal function or heart failure.²⁹ The risk of renal impairment is related to treatment duration and doses, and renal function would improve with discontinuation of the 5-ASA.^{29,30}

5.2. Corticosteroids

Corticosteroids (maximum dose 1 mg/kg/day or 60 mg/day) are standard treatment in induce remission and severe UC.⁶ Budesonide-MMX, a novel oral formulation with less systemic side effects, is recommended for mild to moderate UC.⁶ However, steroid

is not advised for use as maintenance treatment due to adverse events such as hypertension, hypokalemia, hyperglycemia, and mental status changes after long-term use in elderly patients.^{3,10} Osteoporosis-related fracture is an important issue in the elderly patients with IBD, and these patients require calcium, vitamin D, and possibly a bisphosphonate to minimize the complications.³¹

5.3. Immunosuppressants

Immunomodulators should be used in steroid-dependent patients for maintenance therapy.^{6,10} Data from the EPIMAD registry, including 841 patients aged over 65 years at IBD diagnosis, showed that 16% of UC patients received immunosuppressive agents after 10 years and only 3% received anti-TNF therapy.¹ The currently recommended immunosuppressant treatment is azathioprine (AZA) 1.0–2.5 mg/kg.⁶ Adverse events associated with AZA include leukopenia, fever, pancreatitis, and hepatitis. In patients with hypertension, the angiotensin-converting-enzyme inhibitor should be avoided because its interaction with AZA may lead to leukopenia and anemia.³² In elderly patients, male sex and longer duration of AZA treatment are risk factors of developing lymphoma.³³

5.4. Biologic agents

Biologic agents are used in patients failing conventional therapies or who are steroid dependent.^{6,10} There are two mainstream biologic agents approved by the United States Food and Drug Administration for the treatment of UC: anti-tumor necrosis α (anti-TNF) agents (infliximab [IFX], adalimumab [ADA], and golimumab [GOL]), and the more recent anti-integrin agent (vedolizumab [VDZ]).

5.4.1. Anti-tumor necrosis α agents

Anti-TNF agents have become a significant treatment for UC, proving to induce clinical remission with rapid onset.⁶ In elderly patients with UC, anti-TNF would increase the risk of opportunistic infection and mortality.³⁴ Older patients are threefold more likely to quit anti-TNF therapy compared to younger patients and twofold more likely to stop anti-TNF therapy compared to use of immunomodulators.³⁵

IFX is the first and most extensively studied biologic agent, however, there are fewer studies have focused on the safety of IFX in the elderly.^{36,37} Induction of IFX in acute severe UC is more efficacious than other biologics.^{6,36} In an IBD expert group

consensus, IFX usage in patients older than 70 is not recommended but can be used as an alternative to surgery in severe UC.³⁷ ADA attain similar efficacy as IFX on long-term maintenance therapy.³⁶ ADA may be an appropriate option in older patients in whom monotherapy, rather than combination therapy with an immunomodulator.^{6,38} Recently, GOL has shown the same safety and efficacy profile as other anti-TNF agents.³⁸

5.4.2. Anti-integrin agent

VDZ is a novel humanized monoclonal antibody to integrin that selectively inhibits inflammation in the gastrointestinal tract, suggesting lower risks of systemic toxicities and immunosuppression.^{39,40} This drug has a moderate effect and slow onset of action.⁴⁰ VDZ is safe in older patients; however, further large-scale and long-term follow-up studies are still required.^{40–42} The risk factors for serious infection in VDZ are prior failure of anti-TNF and narcotic analgesic use.⁴³

6. Surgical treatment

Bowel perforation, massive bleeding, toxic megacolon, severe colitis unresponsive to medical treatment, high-grade dysplasia, and carcinoma are indications for surgical treatment in patients with UC.⁶ The risk of surgery among older patients is similar to that in younger patients.¹⁰ Sphincter function needs to be carefully evaluated preoperatively if ileal–anal pouch surgery is intended. The incidence of anastomotic leaks and pouch-related complications (Fig. 1) and pouch failure rates do not differ between younger and older patients.⁴⁴ Urgent surgery, low levels of albumin, and male sex are predictors of poor outcome in an elderly population.⁴⁵ The complication and death rates have decreased significantly over time with the advances in perioperative care.^{44,45}

7. Special consideration in elderly patients

Elderly patients with UC are at increased risk of developing colorectal cancers (CRC) (Fig. 2), and the risk increased with the disease extent and duration.⁶ Surveillance guidelines are based on colitis duration, and recommendations are not different for elderly patients.^{3,10} Colonoscopy in elderly patients carries a greater risk of complications, lower completion rates, and higher chance of poor bowel preparation.⁴⁶ The potential benefits are significantly decreased because of shorter life expectancy and greater preva-

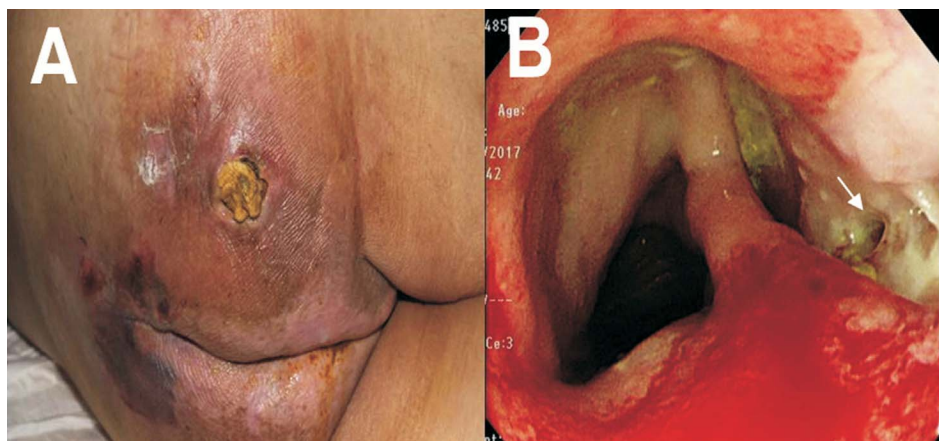


Fig. 1. A 71-year-old man presented with bloody diarrhea after ileal pouch–anal anastomosis for UC. An enterocutaneous fistula occurred between the right buttock (A) and pouch (B).

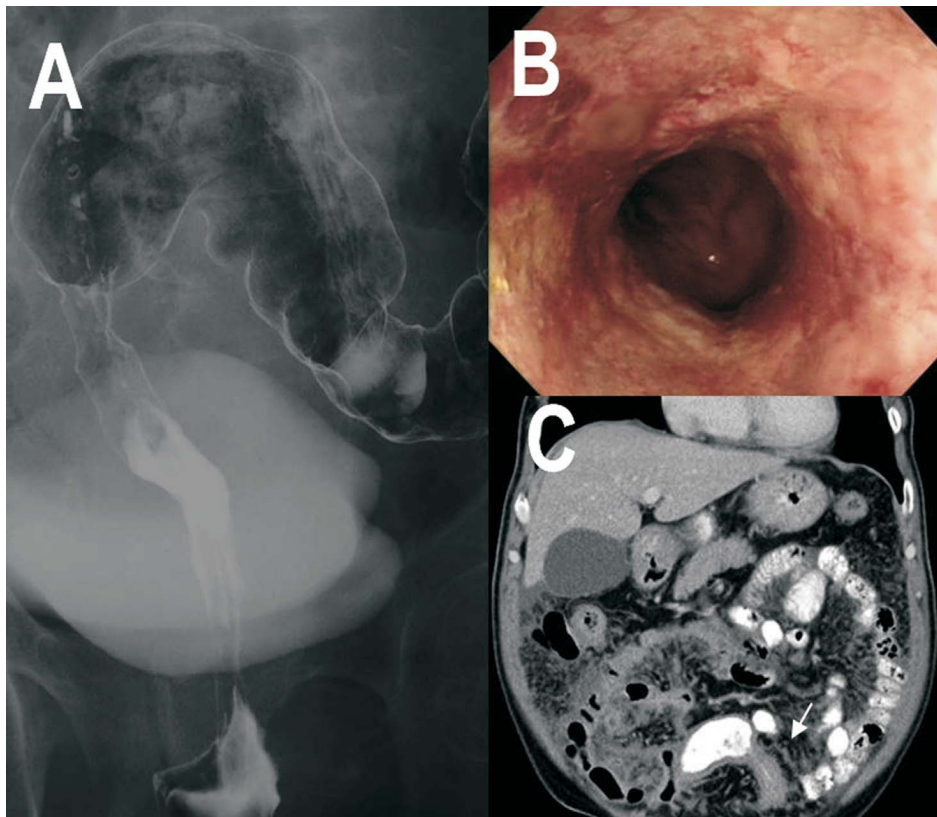


Fig. 2. A 64-year-old man with UC for more than 10 years had constipation. Double colon series showed stricture in the rectosigmoid (A). Repeated biopsy from the stricture area showed only dysplasia (B). Computed tomography revealed peritoneal carcinomatosis (C).

lence of comorbidities in this group. Thus, screening colonoscopy in elderly patients should be performed only after careful consideration of the potential benefits and risks as well as patient preferences.⁴⁶

Patients with IBD treated with corticosteroids, immunomodulators, and biologic agents are at increased risk of developing infectious complications from immune suppression. Thus, elderly patients with additional comorbidities are more susceptible to infection. Verifying vaccination status and regularly vaccinating for influenza, hepatitis B virus, and pneumococcal disease are recommended.⁴⁷

8. Conclusion

With the increasing prevalence of UC among older individuals, clinicians should take care of such specific group with high comorbidity rates and polypharmacy. Diagnosis may be difficult because there are numerous clinical conditions that may mimic UC and some elderly patients with UC present with atypical symptoms. The treatment should consider potential pharmacological interactions and focus on the side effects caused by advanced age.

Conflict of interest

None.

References

- Charpentier C, Salleron J, Savoye G, et al. Natural history of elderly-onset inflammatory bowel disease: a population-based cohort study. *Gut*. 2014;63:423–443.
- Ha CY, Newberry RD, Stone CD, et al. Patients with late-adult-onset ulcerative colitis have better outcomes than those with early onset disease. *Clin Gastroenterol Hepatol*. 2010;5:682–687.
- Katz S, Pardi DS. Inflammatory bowel disease of the elderly: frequently asked questions (FAQs). *Am J Gastroenterol*. 2011;106:1889–1897.
- Prideaux L, Kamm MA, De Cruz PP, et al. Inflammatory bowel disease in Asia: a systematic review. *J Gastroenterol Hepatol*. 2012;27:1266–1280.
- Wei SC, Lin MH, Tung CCA, et al. A nationwide population-based study of the inflammatory bowel diseases between 1998 and 2008 in Taiwan. *BMC Gastroenterol*. 2013;13:166.
- Wei SC, Chang TA, Chao TH, et al. Management of ulcerative colitis in Taiwan: consensus guideline of the Taiwan society of inflammatory bowel disease. *Intest Res*. 2017;15:266–284.
- Lin WC, Tung CC, Lin HH, et al. Elderly adults with late-onset ulcerative colitis tend to have atypical, milder initial clinical presentations but higher surgical rates and aortality: a Taiwan society of inflammatory bowel disease study. *J Am Geriatr Soc*. 2016;64:e95–e97.
- Riegler G, Tartaglione MT, Carratù R, et al. Age-related clinical severity at diagnosis in 1705 patients with ulcerative colitis: a study by GISC (Italian Colon-Rectum Study Group). *Dig Dis Sci*. 2000;45:462–465.
- Seymour K, Richard F. Inflammatory bowel disease of the elderly. *Gastroenterol Hepatol (N Y)*. 2008;4:337–347.
- Taleban S, Colombel JF, Mohler MJ, et al. Inflammatory bowel disease and the elderly: a review. *J Crohns Colitis*. 2015;9:507–515.
- Duricova D, Burisch J, Jess T, et al. Age-related differences in presentation and course of inflammatory bowel disease: an update on the population-based literature. *J Crohns Colitis*. 2014;8:1351–1361.
- Campieri M, Gionchetti P. Bacteria as the cause of ulcerative colitis. *Gut*. 2001;48:132–135.
- Lin WC, Chang CW, Chen MJ, et al. Challenges in the diagnosis of ulcerative colitis with concomitant bacterial infections and chronic infectious colitis. *PLoS One*. 2017;12. e0189377.
- Klauber E, Briski LE, Khatib R. Cytomegalovirus colitis in the immunocompetent host. *Scand J Infect Dis*. 1998;30:559–564.
- Carter D, Olchovsky D, Pokroy R, et al. Cytomegalovirus-associated colitis causing diarrhea in an immunocompetent patient. *World J Gastroenterol*. 2006;12:6898–6899.
- Seo TH, Kim JH, Ko SY, et al. Cytomegalovirus colitis in immunocompetent

- patients: a clinical and endoscopic study. *Hepato-Gastroenterology*. 2012;59:2137–2141.
17. Iwasaki T. Alimentary tract lesions in cytomegalovirus infection. *Acta Pathol Jpn*. 1987;37:549–565.
 18. Cubiella FJ, Núñez CI, González VE, et al. Risk factors associated with the development of ischemic colitis. *World J Gastroenterol*. 2010;16:4564–4569.
 19. Angeliki T, Ioannis EK. Ischemic colitis: clinical practice in diagnosis and treatment. *World J Gastroenterol*. 2008;14:7302–7308.
 20. Green BT, Tendler DA. Ischemic colitis: a clinical review. *South Med J*. 2005;98:217–222.
 21. Cerilli LA, Greenson JK. The differential diagnosis of colitis in endoscopic biopsy specimens: a review article. *Arch Pathol Lab Med*. 2012;136:854–864.
 22. Katsinelos P, Christodoulou K, Pilpilidis I, et al. Colopathy associated with the systemic use of nonsteroidal anti-inflammatory medications. An underestimated entity. *Hepato-Gastroenterology*. 2002;49:345–348.
 23. Marginean EC. The ever-changing landscape of drug-induced injury of the lower gastrointestinal tract. *Arch Pathol Lab Med*. 2016;140:748–758.
 24. Watts DA, Lessells AM, Penman ID, et al. Endoscopic and histologic features of sodium phosphate bowel preparation induced colonic ulceration: case report and review. *Gastrointest Endosc*. 2002;55:584–587.
 25. A1 Chlumská, Benes Z, Mukensnabl P, et al. Histologic findings after sodium phosphate bowel preparation for colonoscopy. Diagnostic pitfalls of colonoscopic biopsies. *Cesk Patol*. 2010;46:37–41.
 26. Kennedy GD, Heise CP. Radiation colitis and proctitis. *Clin Colon Rectal Surg*. 2007;20:64–72.
 27. Lin WC, Chen MJ, Chu CH, et al. Crohn's disease: specific concerns in the elderly. *Int J Gerontol*. 2016;10:126–130.
 28. Pardi DS, Loftus Jr EV, Camilleri M. Treatment of inflammatory bowel disease in the elderly: an update. *Drugs Aging*. 2002;19:355–363.
 29. Corrigan G, Stevens PE. Review article: interstitial nephritis associated with the use of mesalazine in inflammatory bowel disease. *Aliment Pharmacol Ther*. 2000;14:1–6.
 30. Patel H, Barr A, Jeejeebhoy KN. Renal effects of long-term treatment with 5-aminosalicylic acid. *Can J Gastroenterol*. 2009;23:170–176.
 31. Tilg H, Moschen AR, Kaser A, et al. Gut, inflammation and osteoporosis: basic and clinical concepts. *Gut*. 2008;57:684–694.
 32. Kirchertz EJ, Grone HJ, Rieger J, et al. Successful low dose captopril rechallenge following drug-induced leucopenia. *Lancet*. 1981;1:1362–1363.
 33. Beaugerie L, Brousse N, Bouvier AM, et al. Lymphoproliferative disorders in patients receiving thiopurines for inflammatory bowel disease: a prospective observational cohort study. *Lancet*. 2009;374:1617–1625.
 34. Cottone M, Kohn A, Daperno M, et al. Advanced age is an independent risk factor for severe infections and mortality in patients given anti-tumor necrosis factor therapy for inflammatory bowel disease. *Clin Gastroenterol Hepatol*. 2011;9:30–35.
 35. Desai A, Zator ZA, de Silva P, et al. Older age is associated with higher rate of discontinuation of anti-TNF therapy in patients with inflammatory bowel disease. *Inflamm Bowel Dis*. 2013;19:309–315.
 36. Thorlund K, Druyts E, Mills EJ, et al. Adalimumab versus infliximab for the treatment of moderate to severe ulcerative colitis in adult patients naïve to anti-TNF therapy: an indirect treatment comparison meta-analysis. *J Crohns Colitis*. 2014;8:571–581.
 37. Reinisch W, Van AG, Befrits R, et al. Recommendations for the treatment of ulcerative colitis with infliximab: a gastroenterology expert group consensus. *J Crohns Colitis*. 2012;6:248–258.
 38. Biancone L, Annese V, Ardizzone S, et al. Safety of treatments for inflammatory bowel disease: clinical practice guidelines of the Italian group for the study of inflammatory bowel disease (IG-IBD). *Dig Liver Dis*. 2017;49:338–358.
 39. Soler D, Chapman T, Yang LL, et al. The binding specificity and selective antagonism of vedolizumab, an anti-a4b7 integrin therapeutic antibody in development for inflammatory bowel diseases. *J Pharmacol Exp Therapeut*. 2009;330:864–875.
 40. Raine T. Vedolizumab for inflammatory bowel disease: Changing the game, or more of the same? *United European Gastroenterol J*. 2014;2:333–344.
 41. Yajnik V, Khan N, Dubinsky M, et al. Efficacy and safety of Vedolizumab in ulcerative colitis and Crohn's disease patients stratified by age. *Adv Ther*. 2017;34:542–559.
 42. Navaneethan U, Edminister T, Zhu X, et al. Vedolizumab is safe and effective in elderly patients with inflammatory bowel disease. *Inflamm Bowel Dis*. 2017;23. E17.
 43. Colombel JF, Sands BE, Rutgeerts P, et al. The safety of vedolizumab for ulcerative colitis and Crohn's disease. *Gut*. 2017;66:839–851.
 44. Stallmach A, Hagel S, Gharbi A, et al. Medical and surgical therapy of inflammatory bowel disease in the elderly—prospects and complications. *J Crohns Colitis*. 2011;5:177–188.
 45. Gidon A, David BS, Carol AB, et al. Surgery for ulcerative colitis in elderly persons. *Arch Surg*. 2001;136:1396–1400.
 46. Lin OS. Performing colonoscopy in elderly and very elderly patients: risks, costs and benefits. *World J Gastrointest Endosc*. 2014;16:220–226.
 47. Khadija C, Michelle S, Aftab A, et al. Updates in vaccination: recommendations for adult inflammatory bowel disease patients. *World J Gastroenterol*. 2015;21:3184–3196.